

Short Survey

Abrupt Disruption of Nicotine Addiction and Apathy after a Strategic Acute Brain Ischemia

Pablo M. Bagnati¹

How to cite this article:

Bagnati, P. (2021). Abrupt Disruption of Nicotine Addiction and Apathy after a Strategic Acute Brain Ischemia. *Journal of Applied Cognitive Neuroscience*, 2(2), e00204008.
<https://doi.org/10.17981/JACN.2.2.2021.02>

Manuscript received on 13th July 2021
Accepted on 6th December 2021

CASE:

A 62 year old patient with a history of active smoking (30 pack/year, Fagerström Nicotine Dependence Scale: 6) and hypertension developed a sudden onset of remarkable apathy (Starkstein Apathy Scale: 38) simultaneously with an absolute cessation of cigarette and coffee consumption without any withdrawal symptoms. No significant depressive symptoms were detected by the Hospital Anxiety and Depression Scale — Zigmond y Snaith 1983— (score depression = 10) but an abnormal social behavior (social withdraw and indifference to other's feelings) was reported by relatives. Empathy measured by “Reading the Mind in the Eyes” Test of Baron-Cohen was performed with an abnormal result (score of 11). MRI showed acute ischemic strokes in the left caudate head and pallidum (Figure 1 shows an MRI at 6 months of the initial event). Images also showed an old lesion (presumably of a traumatic origin) compromising medial and lateral fronto-orbital cortex, frontal pole, rostral medial frontal and underneath white matters tracts. A second scan with diffusion tensor imaging tractography showed: decreased fiber density in right cingulate bundle, right uncinate fasciculus, and right medial forebrain bundle (Figure 2) according to the orbito-frontal lesion described above.

¹Departament of Cognitive Neurology, Neuropsychiatry and Neuropsychology, FLENI, Buenos Aires, Argentina.

Contact mail: pbagnati@fleni.org.ar

ORCID ID: <http://orcid.org/0000-0003-2801-0537>

Apathy was the most important symptom in this case and the main complain of the relatives, but smoke cessation without abstinence was surprising, because in our experience, most of the patient which develop apathy after stroke remain or increase smoking (Stahl, 2011).

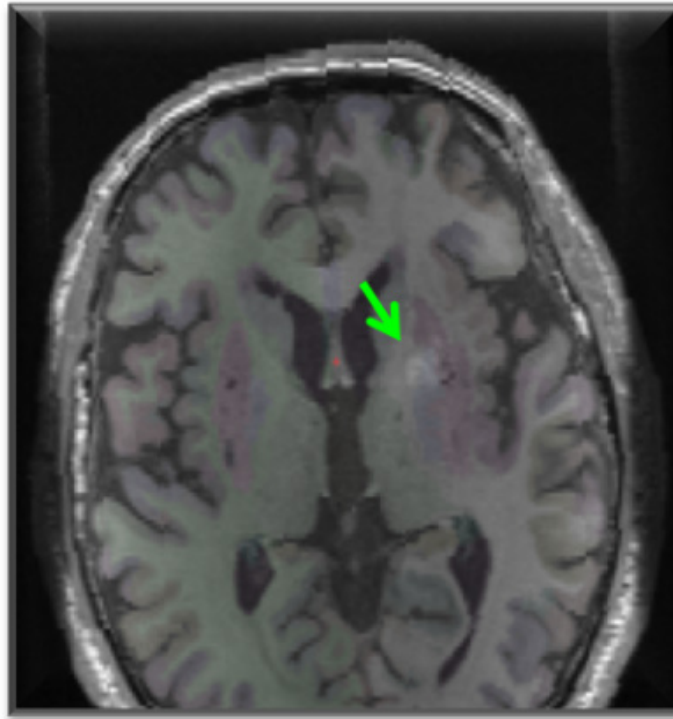


Figure 1. T1 Axial MRI with subcortical labeling. Note the hyperintense signal of the left caudate head and the left pallidum area.

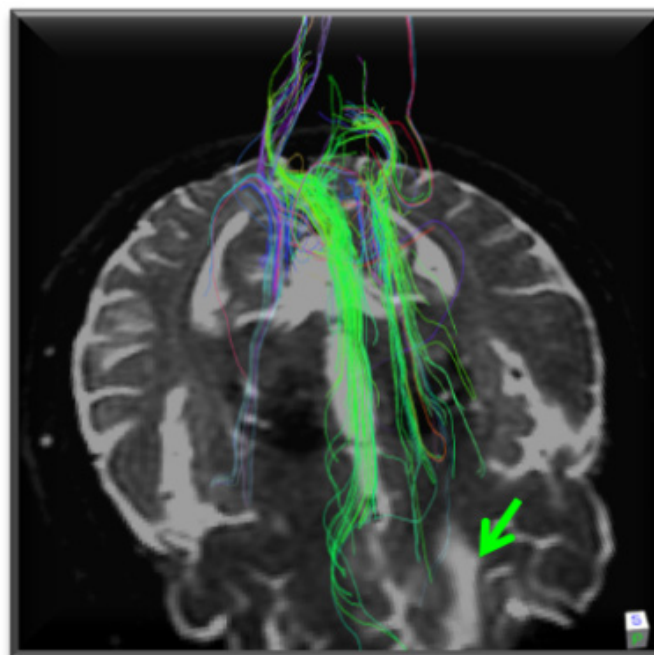


Figure 2. DTI showed decreased fiber density of cingulate bundle, uncinate fasciculus and medial forebrain bundle on the right. The green arrow shows the previous frontal lesion.

DISCUSSION

We considered that the case represents consistent evidence regarding the importance of reward circuit and the intimate mechanisms of apathy, a common and disabling symptom after stroke. Apathy is a neuropsychiatric disorder mostly related to cingulate gyrus damage, superior medial frontal and to disruption of neural networks connecting frontal structures with caudate nucleus, globus pallidus and thalamic nuclei (Jorge, Starkstein & Robinson, 2010). On the other hand there are scarce descriptions of immediate smoke cessation without withdrawal symptoms observed in bilateral pallidum lesions (Miller et al., 2006), posterior right cingulum (Jarraya et al., 2010; Balasubramaniam, Kanaka & Ramanujam, 1973), and after the ischemic lesion in the left caudate nucleus and pallidum area (Muskens, Schellekens, De Leeuw, Tendolkar & Hepark, 2012).

Why if apathy is a very frequently consequence of stroke, smoke cessation is so unfrequently reported? Although apathy is a frequent symptom after a stroke, the abrupt cessation of smoking was unexpected and surprising, opening different causal hypotheses. In regards of the findings of this particular case we hypothesize that the combination of apathy and smoking cessation could be related to a “functional” bilateral fronto-subcortical circuit damage due to a combination of left pallidal and caudate stroke with a deafferentation of the right basal ganglia secondary an old injury (Jarraya et al., 2010; Miller et al., 2006; Muskens et al., 2012).

REFERENCES

- Balasubramaniam, V.; Kanaka, T. S. & Ramanujam, P. B. (1973). Stereotaxic cingulotomy for drug addiction. *Neurology India*, 21(2), 63–66. Available: <https://www.neurologyindia.com/backissues.asp>
- Jarraya, B.; Brugières, P.; Tani, N.; Hodel, J.; Grandjacques, B.; Fénelon, G.; Decq, P. & Palfi, S. (2010). Disruption of cigarette smoking addiction after posterior cingulate damage. *Journal of Neurosurgery*, 113(6), 1219–1221. <https://doi.org/10.3171/2010.6.jns10346>
- Jorge, R. E.; Starkstein, S. E. & Robinson, R. G. (2010). Apathy following stroke. *Canadian Journal of Psychiatry*, 55(6), 350–354. <https://doi.org/10.1177/070674371005500603>
- Miller, J. M.; Vorel, S. R.; Tranguch, A. J.; Kenny, E. T.; Mazzoni, P.; Van Gorp, W. G. & Kleber, H. D. (2006). Anhedonia After a Selective Bilateral Lesion of the Globus Pallidus. *The American Journal Psychiatry*, 163(5), 786–188. <https://doi.org/10.1176/ajp.2006.163.5.786>
- Muskens, J. B.; Schellekens, A. F. A.; De Leeuw, F. E.; Tendolkar, I. & Hepark, S. (2012). Damage in the dorsal striatum alleviates addictive behavior. *General Hospital Psychiatry*, 34(6), 581–587. <https://doi.org/10.1016/j.genhosppsych.2012.01.008>
- Stahl, S. M. (2011). Rewards Disorders, drug abuse and treatment. In: S. M. Stahl, *Stahl's essential psychopharmacology: neuroscientific basis and practical applications*. 3 ed. (Chapter 19, pp. 943–959). Cambridge: CUP.